

# OPHTHAL

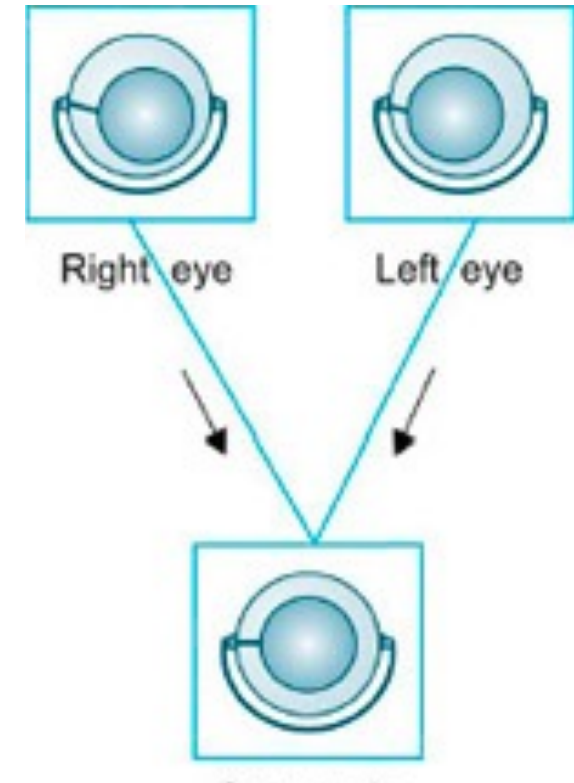
---

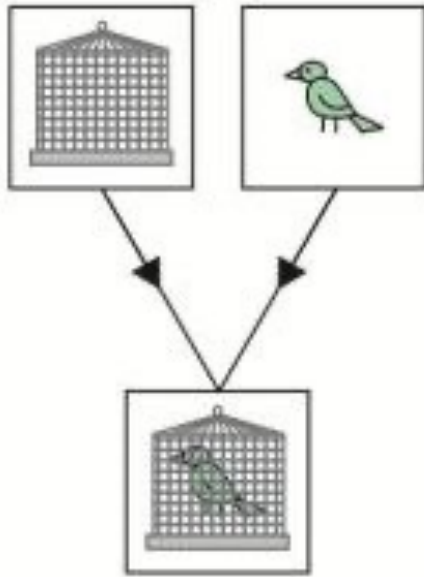
## 2. Which of the following statements about eye development is incorrect?

- A. Full visual acuity develops by 6 years of age
- B. The macula is fully formed at ~~birth~~ 4 months — binocular vision
- C. The cornea reaches adult diameter by the age of 2
- D. The lens continues to grow throughout life

## 8. The binocular vision grade shown in the image corresponds to:

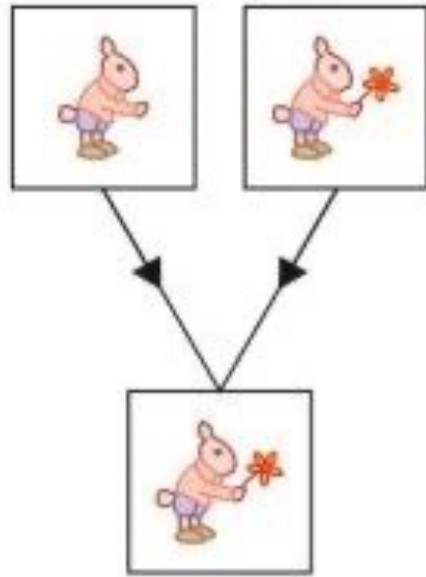
- A. Grade III
- B. Grade IV ~~XX~~
- C. Grade II
- D. Grade I





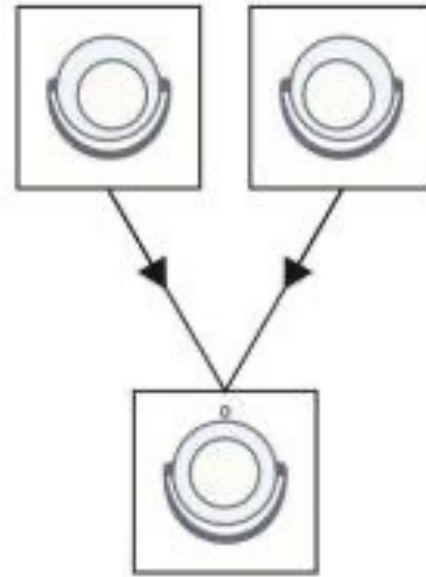
Simultaneous perception

I



Fusion

II



Stereopsis



III

19. A 50-year-old male seeks surgical correction for hypermetropia. Which among the following is not a suitable treatment?

- A. Conductive keratoplasty
- ~~B. Photorefractive keratectomy~~
- C. Thermal laser keratoplasty
- D. Hyperopic photorefractive keratotomy

## Hypermetropia

Cornea based procedures	Lens-based procedure
Thermal laser keratoplasty (TLK)	Refractive lens exchange
Hyperopic photorefractive keratotomy	Phakic intraocular lens
Conductive keratoplasty	



## Myopia

Cornea-based procedures	Lens-based procedures
<b>Laser-based:</b>	
• Photorefractive keratectomy (PRK)	Refractive lens exchange
• Laser in-situ keratomileusis (LASIK) (Most common)	Phakic intraocular lens (ICL)
• Refractive lenticule extraction (ReLEx) or Small incision lenticule extraction (SMILE)	Clear lens extraction
• Intracorneal ring segment (ICRS) implantation	
• Orthokeratology	
• Radial keratotomy (obsolete) → (x) bmea	

23. A student with **myopia** wishes to undergo surgery. Which option is **not** suitable for correcting her refractive error?

- A. SMILE
- B. Radial keratotomy
- C. Intracorneal ring implantation
- D. **Conductive keratoplasty**

26. What is the primary material used in manufacturing soft contact lenses?

- A. Cellulose acetate butyrate
- B. Polymethylmethacrylate
- C. Hydroxyethyl methyl acrylate
- D. Silicone

**Hard lenses:**

- Made of **PMMA** (polymethylmethacrylate)

**Rigid gas permeable / Semi-soft lenses:**

- Made of **silicone acrylate** and **cellulose acetate butyrate (CAB)**

**Soft lenses:**

- Made of **HEMA** (hydroxy ethyl methyl acrylate)


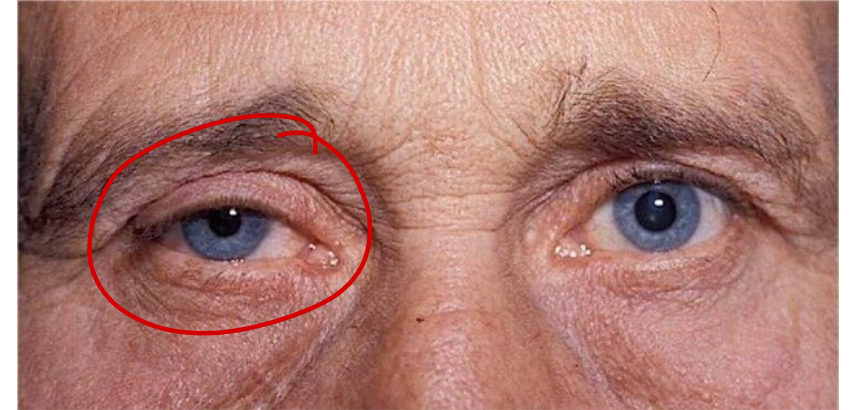
28. A 2-year-old child with leukocoria and calcified intraocular masses is found to have tumors 4–10 DD in size behind the equator. According to Reese-Ellsworth classification, to which group does this case belong?

- A. Group 3
- B. Group 1
- C. Group 2
- D. Group 4

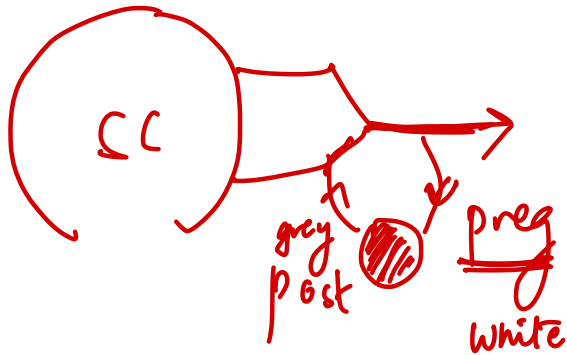
Group	Prognosis for Maintenance of Sight	Features
1	Very favourable	- Solitary or multiple tumor < 4 DD, at or behind equator
2	Favourable	- Solitary or multiple tumor 4–10 DD, behind equator
3	Possible	- Any lesion anterior to equator
		- Solitary tumor > 10 DD behind equator
4	Unfavourable	- Multiple tumors, some >10 DD
		- Any lesion extending anteriorly to ora serrata
5	Highly unfavourable	- Massive tumors involving > half of retina
		- Vitreous seeding

33. A construction worker has unilateral facial anhidrosis after a back injury. Examination finding is shown below. Which location is the most likely site of lesion?

- A. Grey ramus of T1
- B. Grey ramus of C8
- C. White ramus of T1
- D. White ramus of C8

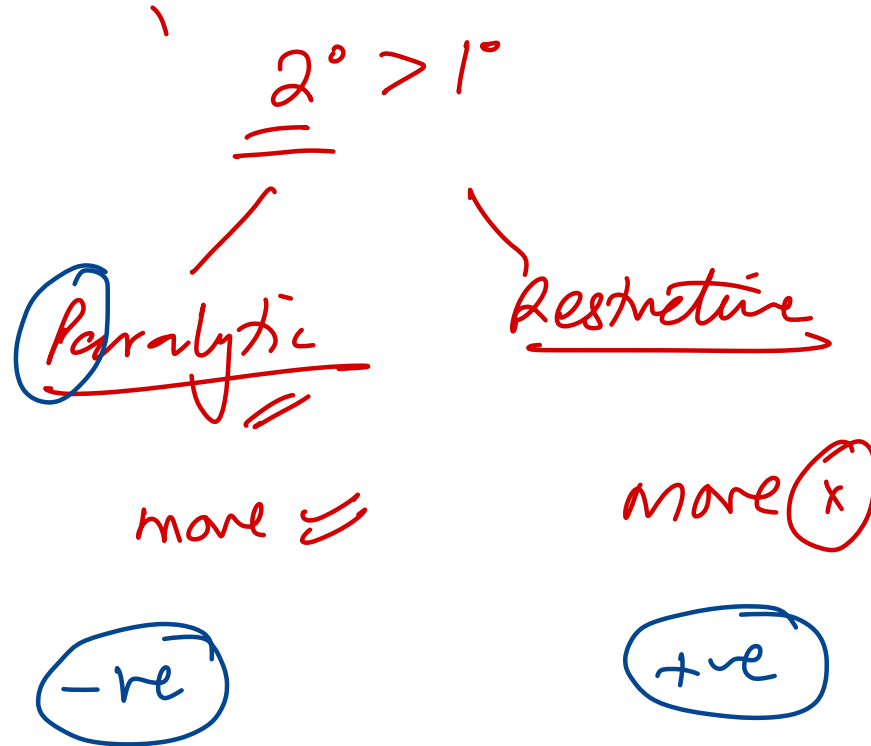


ptosis - Muller's  
Enophthalmos  
Miosis



35. A 40-year-old diabetic patient presented with the squint. On examination, the secondary deviation was found to be more than the primary deviation. Forced duction test is negative. Which of the following types of squint is most likely to be present in this patient?

- A. Concomitant squint
- B. Restrictive squint
- C. Paralytic squint
- D. Pseudosquint



NP:  $1^\circ = 2^\circ$

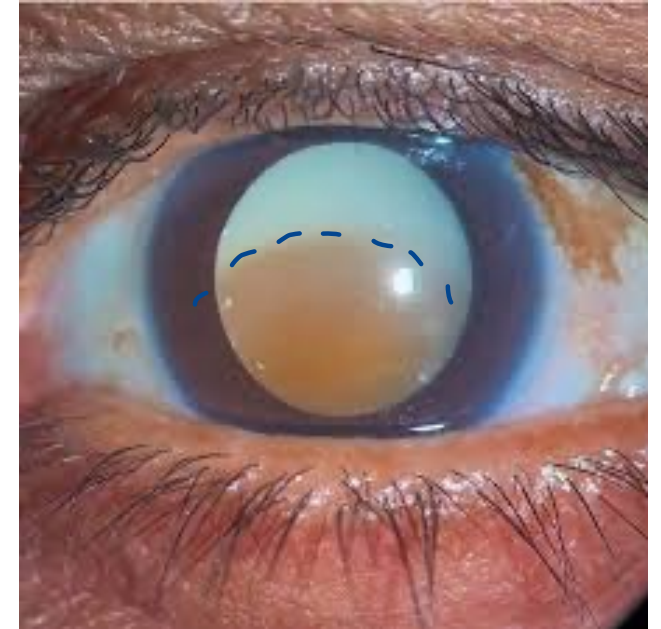
38. 65-year-old woman with senile cataract shows the following findings.  
What is the stage of the cataract? →

A. Intumescent cataract

B. Morgagnian cataract *Liquefactive*

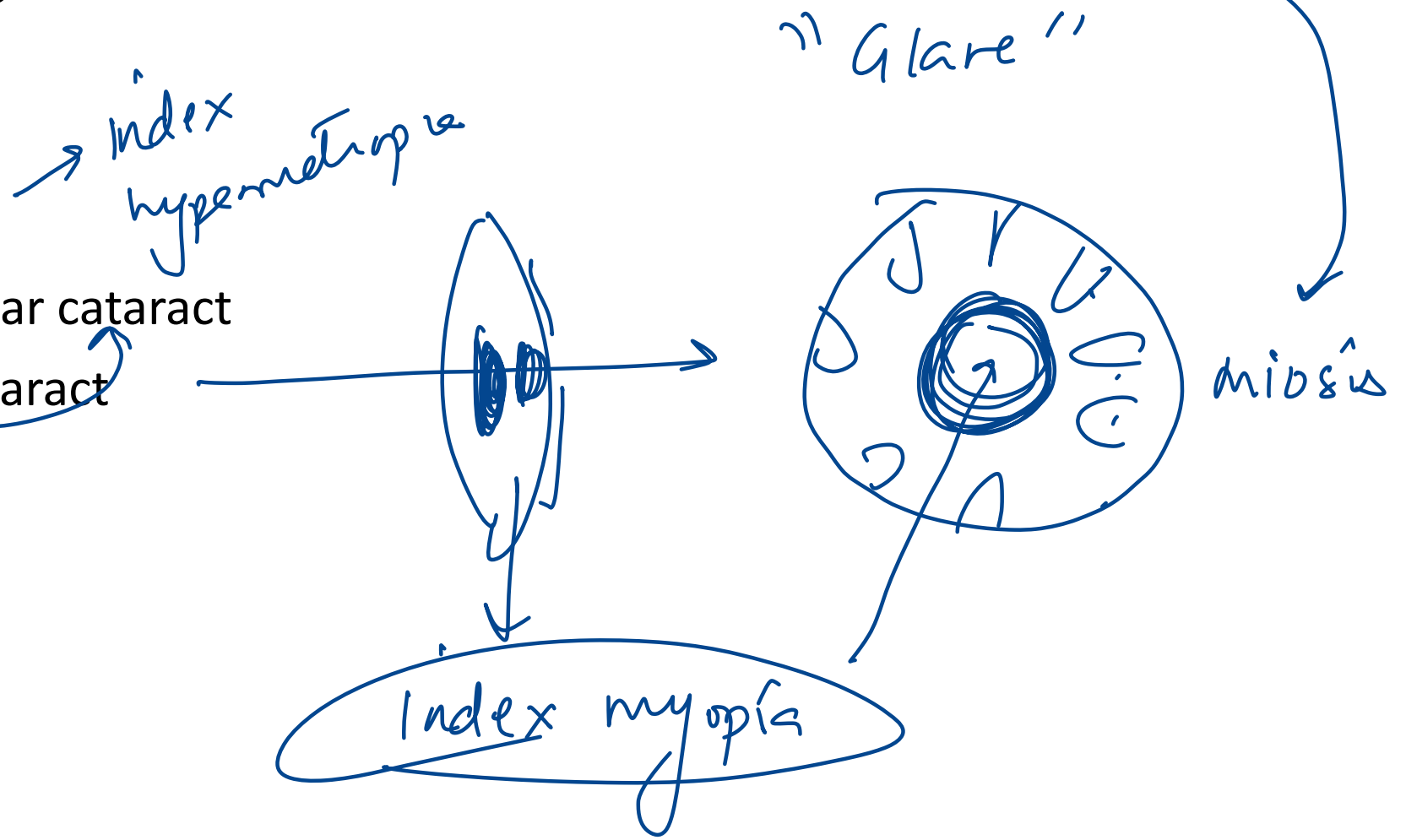
C. Mature senile cataract

D. Sclerotic hypermature cataract



41. A 55-year-old woman has difficulty seeing in bright light and is diagnosed with a cataract. Which cataract type is not typically associated with this symptom?

- A. Nuclear cataract
- B. Cuneiform cataract
- C. Posterior subcapsular cataract
- D. Steroid-induced cataract



44. A 14-day-old neonate born at 28 weeks of gestation had developed respiratory distress syndrome at birth. You want to screen for retinopathy of prematurity. How many weeks from now would you schedule the screening?

A. 4 weeks

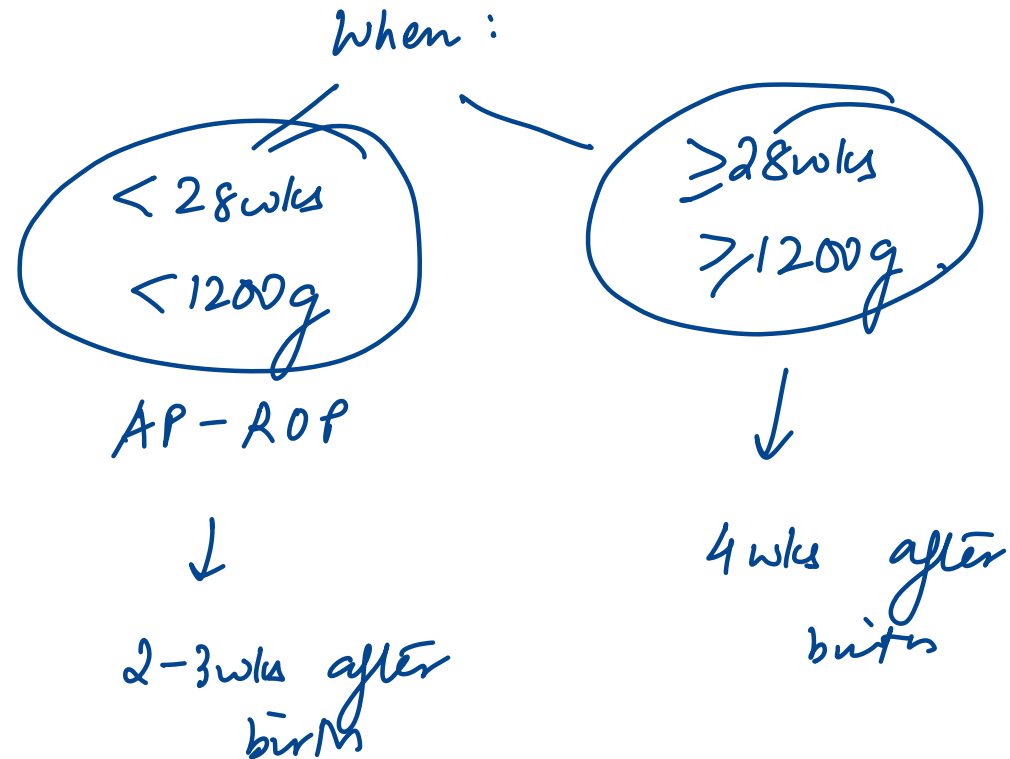
B. 2 weeks



C. 8 weeks

D. 12 weeks

### Who to screen:

- Birth weight  $\leq 2000$  g
- Gestational age  $\leq 34$  weeks
- Sick infants (oxygen therapy, sepsis, blood transfusions, etc.)



Stage	Description
Stage 1 	Demarcation line between vascular and avascular retina
Stage 2 	Elevated ridge at the demarcation line
Stage 3	Ridge with extraretinal fibrovascular proliferation
Stage 4A	Partial retinal detachment not involving the macula
Stage 4B	Partial retinal detachment involving the macula
Stage 5	Total retinal detachment

### Plus Disease

- **Definition:** Arteriolar tortuosity and venous dilation in posterior pole
- Indicates active, progressive disease
- Can occur with any stage, requires prompt treatment

Condition	Management
No ROP or Stage 1/2 without plus disease	Observation and serial retinal exams
Stage 3 with plus disease (Threshold ROP)	Laser photocoagulation of avascular retina (gold standard)
Zone I or posterior Zone II with plus disease	Intravitreal anti-VEGF agents (e.g., bevacizumab) preferred
Stage 4 or 5	Surgical intervention (e.g., vitrectomy)
APROP	Early anti-VEGF + laser combination therapy

# 45. In which of the following situations is retrobulbar block considered safe

A. Penetrating eye trauma

B. High myopia

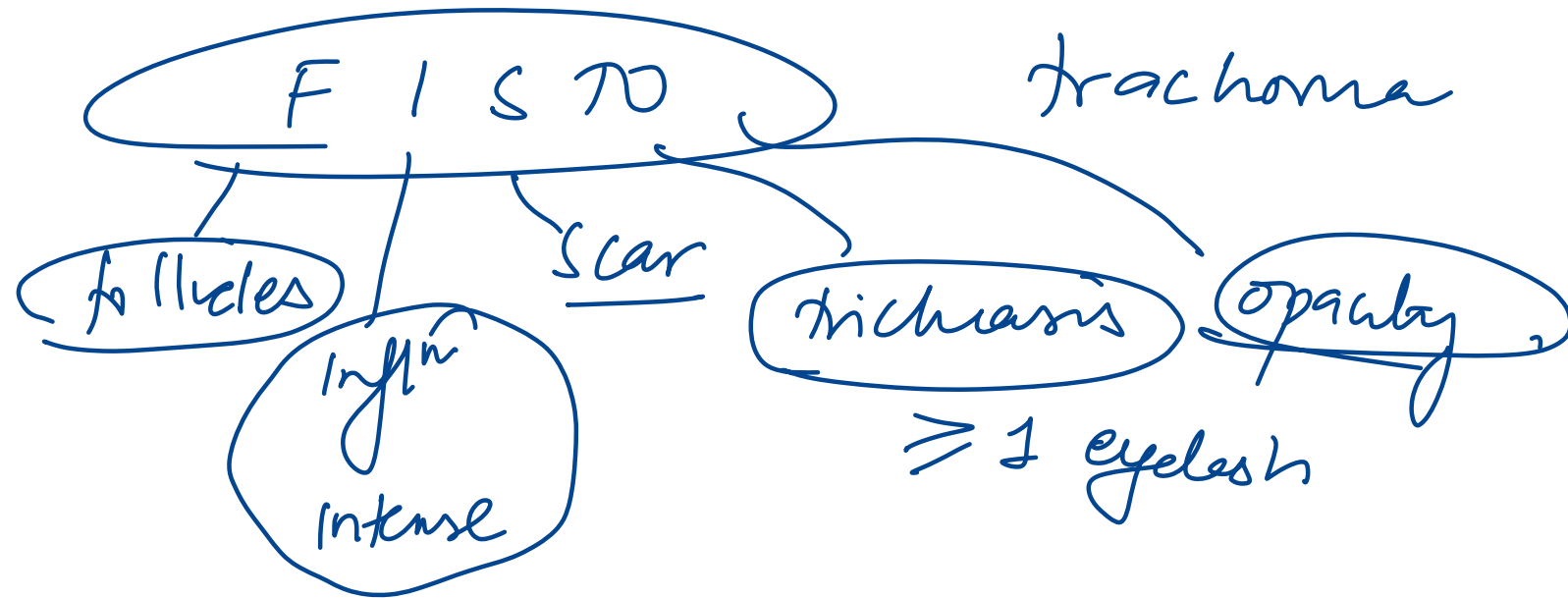
C. Coagulopathy

D. Enucleation



## 50. According to the grading of trachoma, what defines the follicular stage?

- A. 5 or more follicles in the upper tarsal conjunctiva
- B. 3 or more follicles in the lower tarsal conjunctiva
- C. 5 or more follicles in the lower tarsal conjunctiva
- D. 3 or more follicles in the upper tarsal conjunctiva



50% surface obscured.

## 123. All are true about diabetic retinopathy features except:

- A. NVD of any disc area with VH is high-risk ✓
- B. Vitreous hemorrhage with NVE is a high-risk feature ✓
- C. Clinically significant macular edema includes thickening within 500 μm of fovea ✓
- D. ~~Tractional retinal detachment~~ is a sign of ~~NPDR~~ Advanced eye ✓

*glycemic control*

**Mild NPDR**

• At least one microaneurysm must be present

**Moderate NPDR**

- Microaneurysms/intraretinal hemorrhages in 2–3 quadrants
- Early IRMA (intraretinal microvascular abnormalities)
- Hard exudates and cotton-wool spots may or may not be present

**Severe NPDR (4-2-1 rule) – any one of:**

- 4 quadrants of microaneurysms/intraretinal hemorrhages
- 2 quadrants of venous beading
- 1 quadrant of IRMA changes

**Very Severe NPDR – any two of the 4-2-1 features above**

*VEGF ⊖*

**•Early PDR (without high-risk characteristics):**

- Neovascularization at optic disc (NVD) or elsewhere (NVE)

**•High-risk PDR:**

- NVD < 1/4 disc area + VH or PRH
- NVD 1/4–1/3 disc area ± VH or PRH
- NVE > 1/2 disc area + VH or PRH

**Clinically Significant Macular Edema (CSME)**

(Any 1 of the 3 criteria):

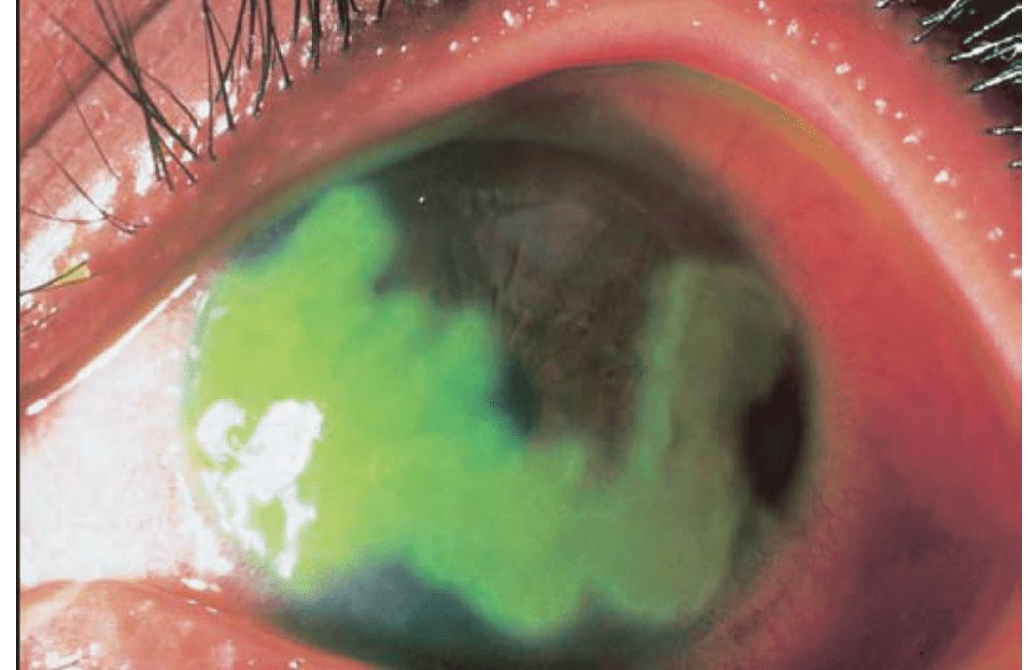
- Thickening of retina within 500 microns of foveal center
- Hard exudates within 500 microns of center
- Zone of retinal thickening ≥ 1 DD

**Advanced Diabetic Eye Disease:**

- Persistent vitreous hemorrhage
- Tractional retinal detachment
- Neovascular glaucoma

**130. A patient presents with a geographic ulcer of the eye. What historical finding is most likely?**

- A. Chronic dacryocystitis
- B. Use of contact lenses
- C. Working with infrared radiation
- D. Use of topical steroids



## 128. All are true about Foster–Kennedy syndrome except:

A. Ipsilateral optic atrophy

B. Often caused by olfactory meningioma

frontal lobe

~~C.~~ Can be seen in occipital lobe neoplasms

D. Contralateral papilledema

**135. Which surgery is most appropriate for a patient with congenital ptosis and poor levator action?**

- A. Fasanella–Servat
- B. Levator resection (anterior approach)
- C. Levator resection with aponeurotic reinsertion
- D. Frontalis suspension with fascia lata**

Surgery	Levator Action	Ptosis Treated
<b>Fasanella-Servat</b>	Good (Horner's syndrome)	<2 mm
<b>Levator Resection</b>	Moderate	Any
<b>Frontalis Suspension - Fascia lata</b>	Poor Congenital ptosis - Marcus-Gunn ptosis	>2 mm

## 197. All are true about corneal dystrophies and stains used except:

- A. Macular dystrophy stains with Alcian blue ✓
- B. Schnyder's dystrophy shows mucopolysaccharides with Congo red ✗
- C. Granular dystrophy is stained by Masson trichome
- D. Lattice dystrophy has amyloid deposition

## Stromal dystrophies

Dystrophy	Substance Deposited	Stain Used
✓ Granular dystrophy	Hyaline	Masson's trichrome
✓ Lattice dystrophy		
<u>Gelatinous drop-like dystrophy</u>	Amyloid	✓ Congo-red
<u>Avellino</u> (Lattice + Granular combo)	Amyloid and hyaline	Congo red and Masson trichrome
<u>Macular dystrophy</u>	<u>Mucopolysaccharide</u>	Alcian blue
<u>Schnyder's crystalline dystrophy</u>	<u>Phospholipids</u>	<u>Oil red-O</u>

180. A patient complains of "fluctuating refractory error". What is the most probable diagnosis?

- A. Cortical cataract
- B. Nuclear cataract
- C. Posterior subcapsular cataract
- ~~D. Diabetic cataract~~

'myopic shift'

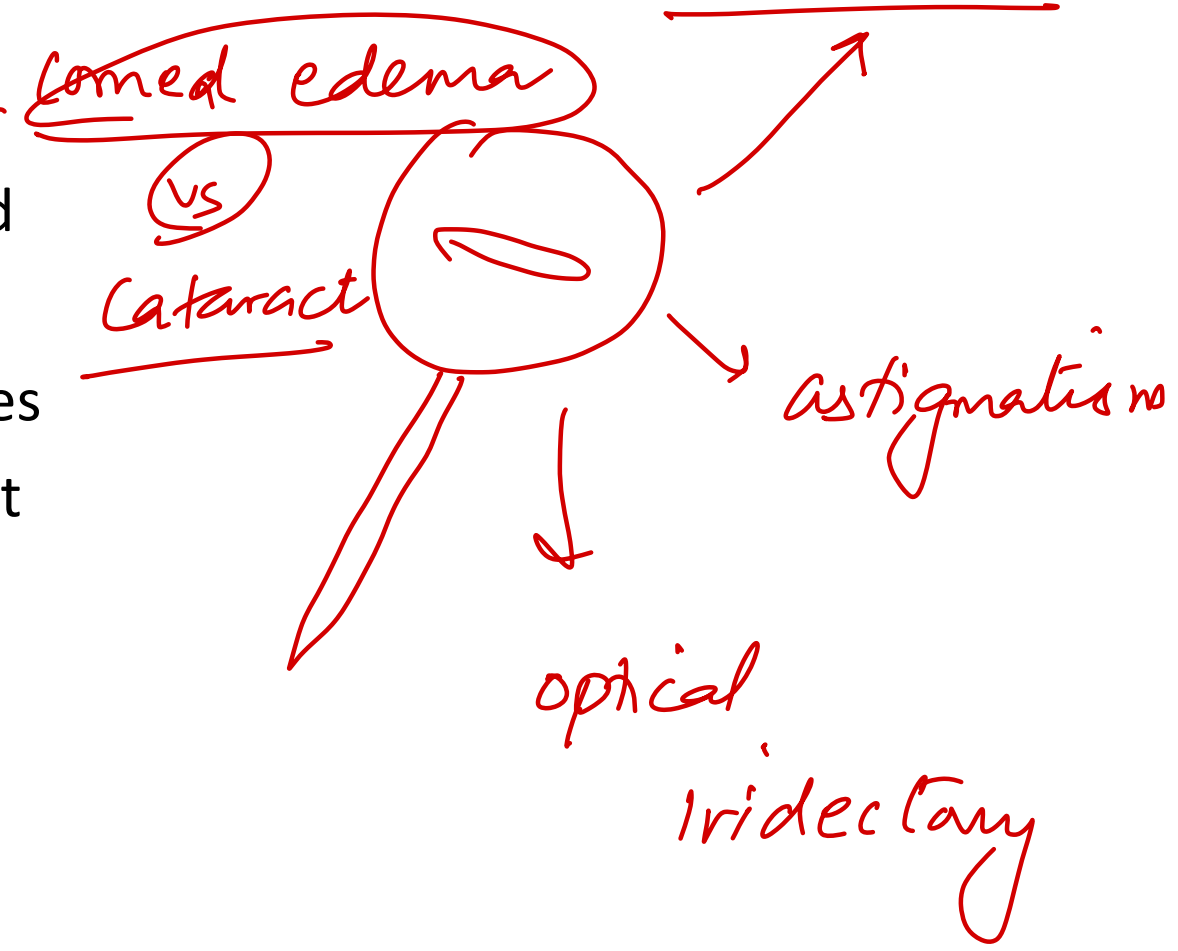
osmotic

imbalance

Sorbitol

174. Which of the following statements best describes the Fincham's test result in a patient with lenticular halo?

- A. Halos remain intact but brightness is reduced
- B. Halos disappear completely
- C. Halos are broken and revolve as the slit moves
- D. No halos are visible through the stenopaic slit



148. MK medium used for corneal preservation is effective for:

A. 7 to 14 days

B. 30 days

C. 1 year ✓ *Cyopt*

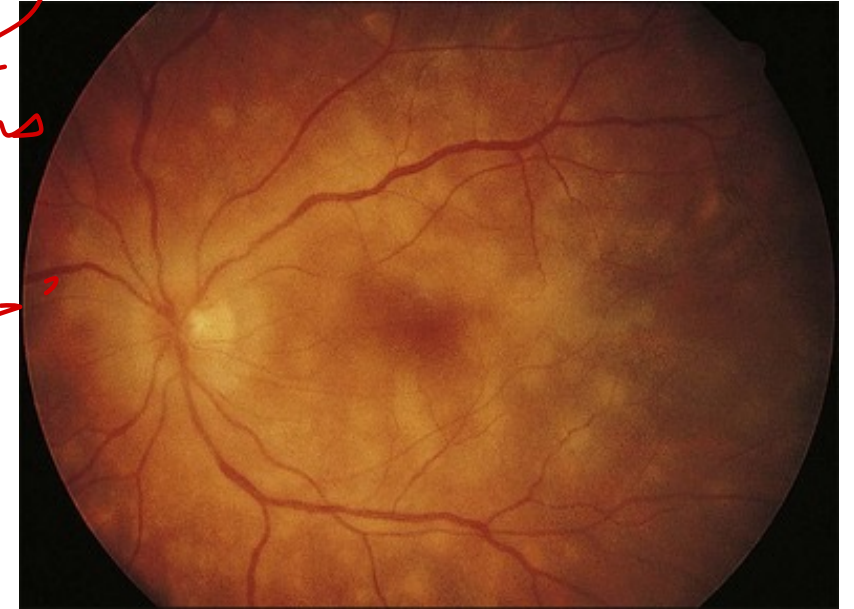
D. 48 to 72 hours

*Short term*

103. A carpenter develops bilateral eye irritation and vision loss after trauma to the right eye. Fundus exam reveals Dalen-Fuchs nodules. Which type of hypersensitivity is involved?


- A. Type 1
- B. Type 2
- C. Type 3
- D. Type 4

SO  
granulomatous  
panuveitis



157. A patient presents with sudden painless loss of vision. Which is the least likely cause?

- A. Retinal detachment involving macula
- B. Central retinal artery occlusion
- ~~C. Optic atrophy~~
- D. Vitreous hemorrhage



### **Sudden painless loss of vision**

- Central retinal artery occlusion
- Massive vitreous hemorrhage
- Retinal detachment involving macula
- Ischemic central retinal vein occlusion

### **Sudden painful loss of vision**

- Acute congestive glaucoma
- Acute iridocyclitis
- Injury to eyeball

### **Gradual painless diminution of vision**

- Corneal dystrophy
- Senile cataract
- Primary open angle glaucoma
- Optic atrophy
- Age-related macular degeneration (ARMD)
- Refractive error
- Diabetic retinopathy

# 194. All are true about the oculocardiac reflex except:

- A. A) Mediated via V1 trigeminal afferent - X efferent - ↓ HR
- B. B) Triggered during strabismus surgery ✓
- C. ~~C) Most commonly due to inferior rectus stimulation~~ (MR)
- D. D) Managed by stopping surgical stimulation

**ENT**

---

39. In acute suppurative otitis media, during which phase is the ear pain at its peak intensity?

A. Stage of resolution

B. Stage of tubal occlusion

~~C.~~ Stage of suppuration

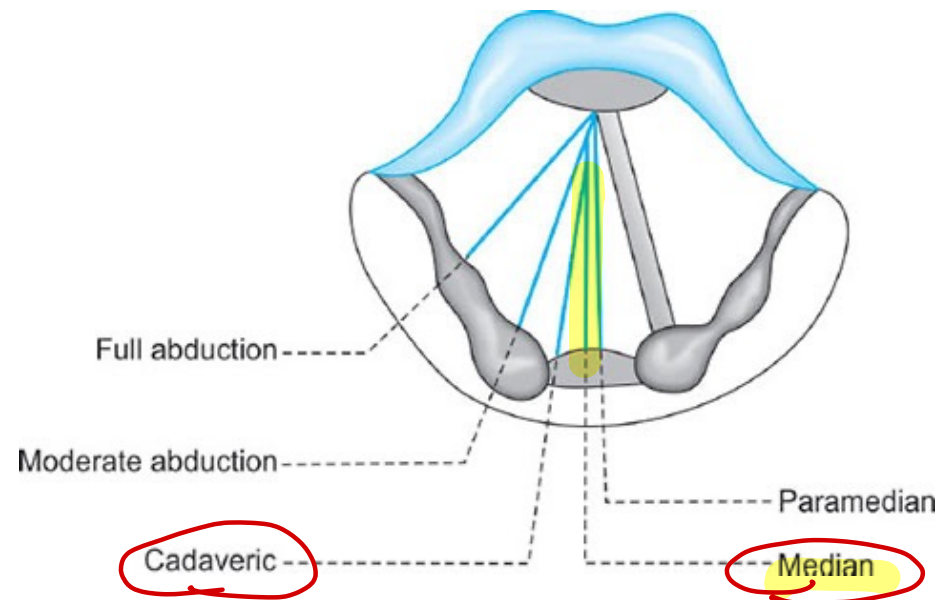
D. Stage of pre-suppurative

147. What position will the vocal cords most likely be in after complete bilateral paralysis following total thyroidectomy?

- A. Paramedian
- B. Median
- ~~C. Intermediate~~ (3mm)
- D. Full abduction

Cadaveric

Position	Distance from Median	Seen in
Median	0 mm	During speech/swallowing
Paramedian	1 mm	Recurrent laryngeal nerve palsy
Intermediate/Cadaveric	3 mm	Complete paralysis
Slight abduction	7 mm	Normal respiration
Full abduction	9 mm	Strained respiration



**133. A 30-year-old man with a history of chronic otitis media presents for tympanoplasty. During the surgery, the surgeon finds that both the malleus and incus are absent. According to Wullstein's classification, which type of tympanoplasty is most appropriate for this patient?**

- A. Type I
- B. Type II
- C. Type III
- D. Type IV

Type 1	<u>Myringoplasty</u>	TM placed over <u>malleus</u>
Type 2	TM grafted over incus	
Type 3	<u>Columella</u> tympanoplasty OR myringostapediopexy	TM grafted over <u>stapes</u>
Type 4	Round window <u>shielding</u>	Oval window out
Type 5	<u>Fenestration</u>	Lateral SCC opening.

135. Austin's classification of ossicular chain defects is based on which components?

- A. Malleus handle and stapes suprastructure
- B. Malleus handle and stapes footplate
- C. Malleus head and stapes suprastructure
- D. Malleus head and stapes footplate

Inius

Group	Ossicular Status	Abbreviation	Prevalence (%)
<b>A</b>	Malleus handle and stapes superstructure present	M+ S+	<u>60</u>
<b>B</b>	Malleus handle present, stapes superstructure absent	M+ S-	23
<b>C</b>	Malleus handle absent, stapes superstructure present	M- S+	8
<b>D</b>	Malleus handle and stapes superstructure absent	M- S-	8

165. All of the following are correctly matched congenital pinna anomalies, except:

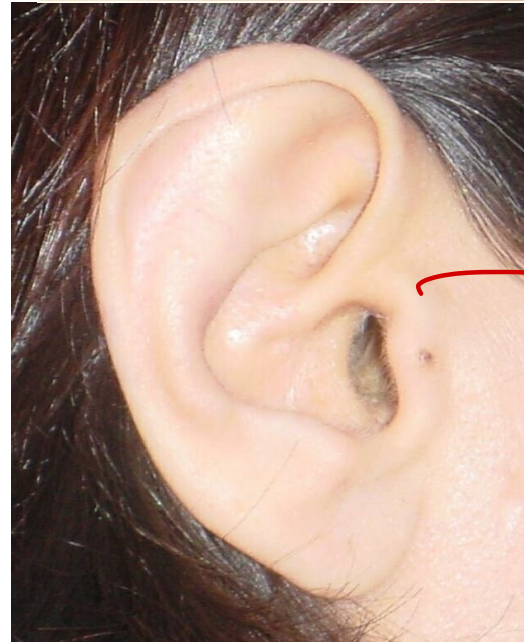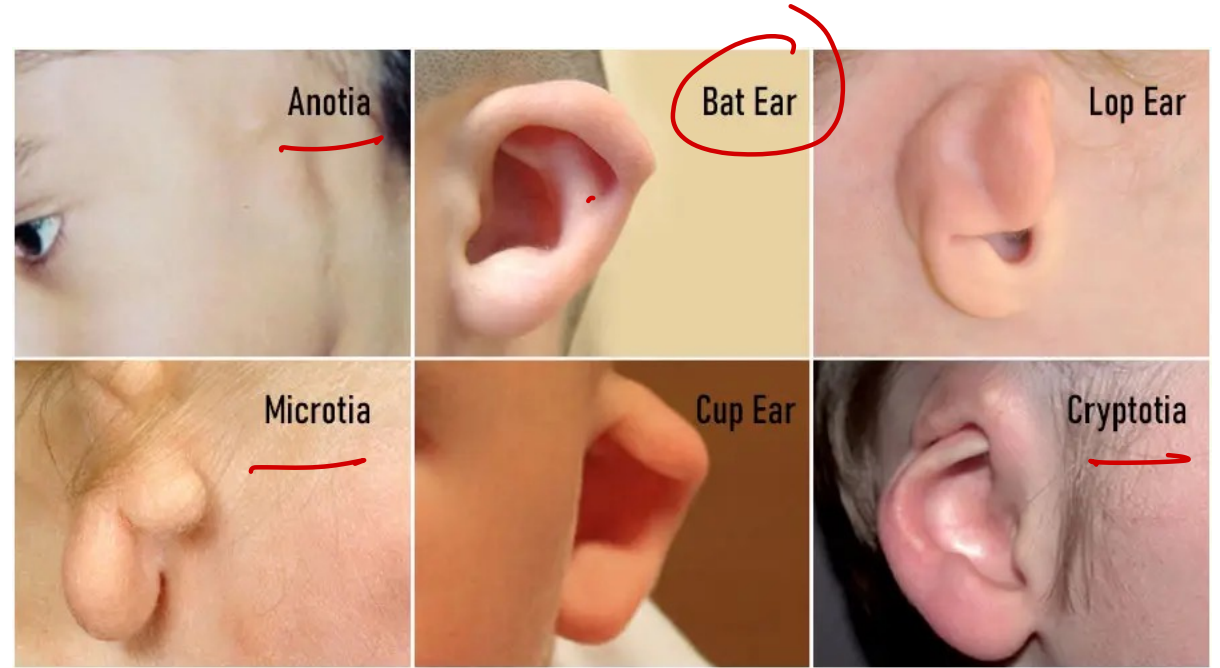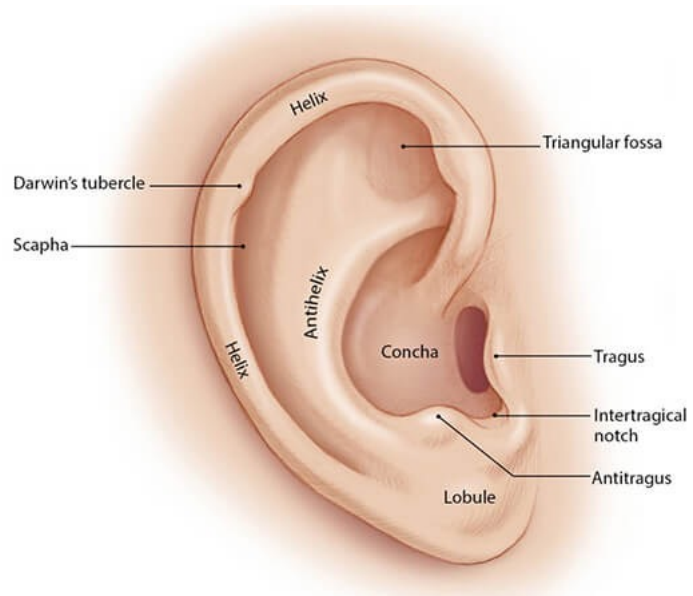
A. Microtia – Small pinna

B. Mozart ear – Fusion of helix and antihelix

C. Wildermuth ear – Large pinna

D. Bat ear – Absent anti-helix

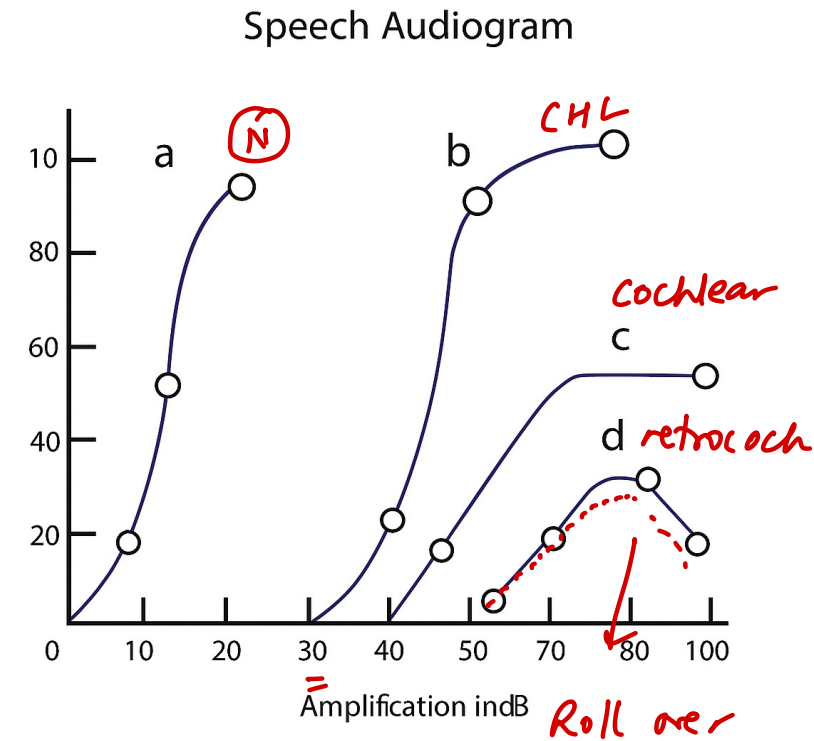
*helix upward - antihelix prominent.*



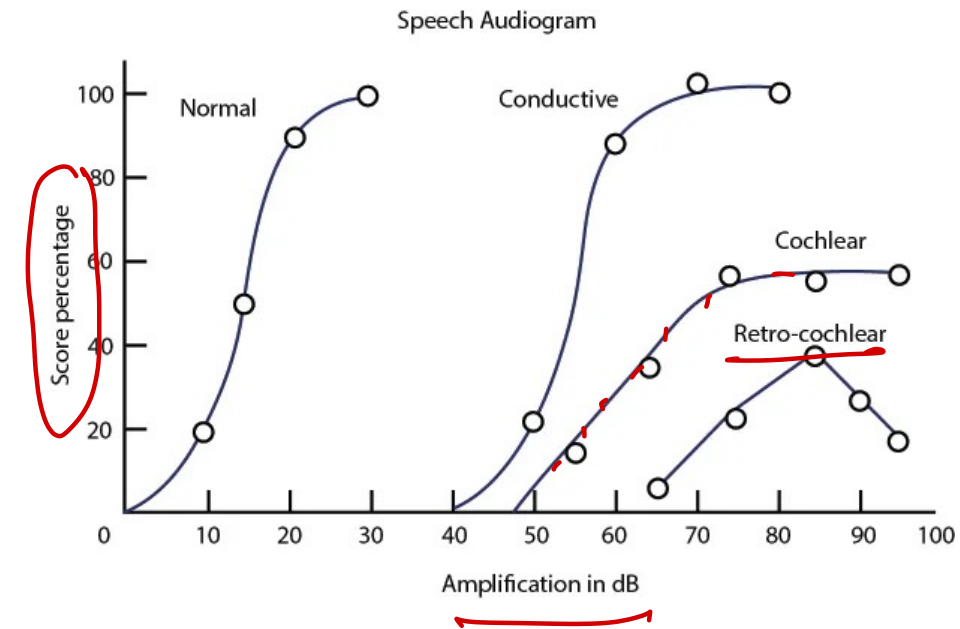
*Wildemann*

# 168. Which of the following audiogram patterns suggests retrocochlear pathology?

- A. A
- B. B
- C. C
- D. D



	NORMAL	COCHLEAR LESION	RETROCOCHLEAR LESION
Pure tone audiogram	Normal	Sensorineural hearing loss	Sensorineural hearing loss
Speech discrimination score	90-100%	Below 90%	Very poor
Roll over phenomenon	Absent	Absent	Present
Recruitment	Absent	Present	Absent
SISI score	0-15%	Over 70%	0-20%
Threshold tone decay test	0-15% dB	Less than 25dB	Above 25dB
Stapedial reflex	Present	Present	Absent
Stapedial reflex decay	Normal	Normal	Abnormal



### SISI (Short Increment Sensitivity Index) Test

• **Purpose:** Assesses the ability to detect small (1 dB) changes in sound intensity.

• **Interpretation:**

- **High score (>70%)** → **Cochlear lesion**
  - Patient detects small intensity changes easily.
- **Low score (0-20%)** → **Retrocochlear lesion or normal**
  - Poor ability to detect small changes.

### Recruitment

• **Definition:** Abnormal growth of perceived loudness with increasing sound intensity.

• **Seen in: Cochlear lesions**

- Soft sounds are not heard.
- Slightly louder sounds suddenly become uncomfortably loud

# 169. All of the following statements regarding the tympanic membrane are correct, except:


- A. The middle layer of the tympanic membrane is derived from mesoderm and contains radial, circular, and parabolic fibers
- B. The outer epithelial layer is continuous with the skin of the external auditory canal and is derived from ectoderm
- C. The inner mucosal layer is derived from ~~ectoderm~~ <sup>endo.</sup> and is continuous with the middle ear mucosa
- D. The region called Shrapnell's membrane does not transmit sound PF



	ecto	<u>meso</u>	endo
	<u>epith</u>	<u>fibrous</u>	<u>mucosal</u>
PT	✓	✓	✓
PF	✓	x	✓

**171. All of the following statements regarding the external auditory canal are correct, except:**

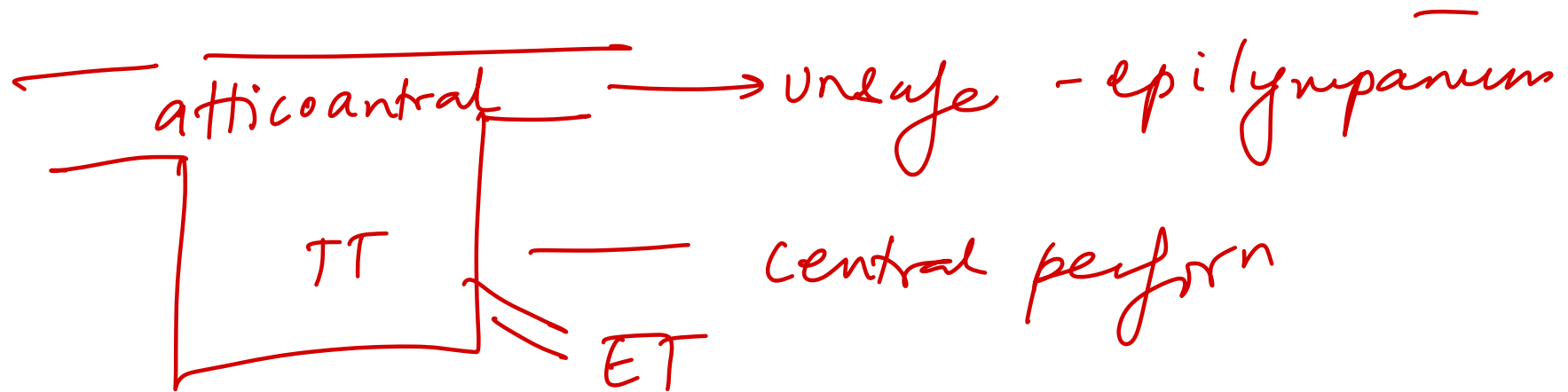
- A. The lateral one-third is made of auricular yellow elastic cartilage (T) (C)
- ~~B. The bony part of the canal is lined with thick skin containing ceruminous glands~~ XX
- C. The medial two-thirds is formed by the temporal bone
- D. Fissures of Santorini are seen in the cartilaginous part



Part	<b>C</b> artilaginous	Bony
Proportions	Lateral 1/3	Medial 2/3
Length	8 mm	16 mm
Made of	Auricular yellow elastic cartilage	Bony margins of the temporal bone
Direction	<sup>A</sup> Upward, <sup>B</sup> backward, medially	Downward, forward, medially
Skin is	Thick Hair, ceruminous & pilosebaceous glands. Produce wax	Thin, <u>continuous over tympanic membrane</u>
Deficiencies	Fissures of Santorini	Foramen of Huschke

173. All of the following are features of attico-antral type of chronic suppurative otitis media (CSOM), except:

- A. Also called the unsafe type ✓
- B. Cholesteatoma is present ✓
- C. Central perforation in the anteroinferior quadrant
- D. Granulations and red fleshy polyps are common ✓



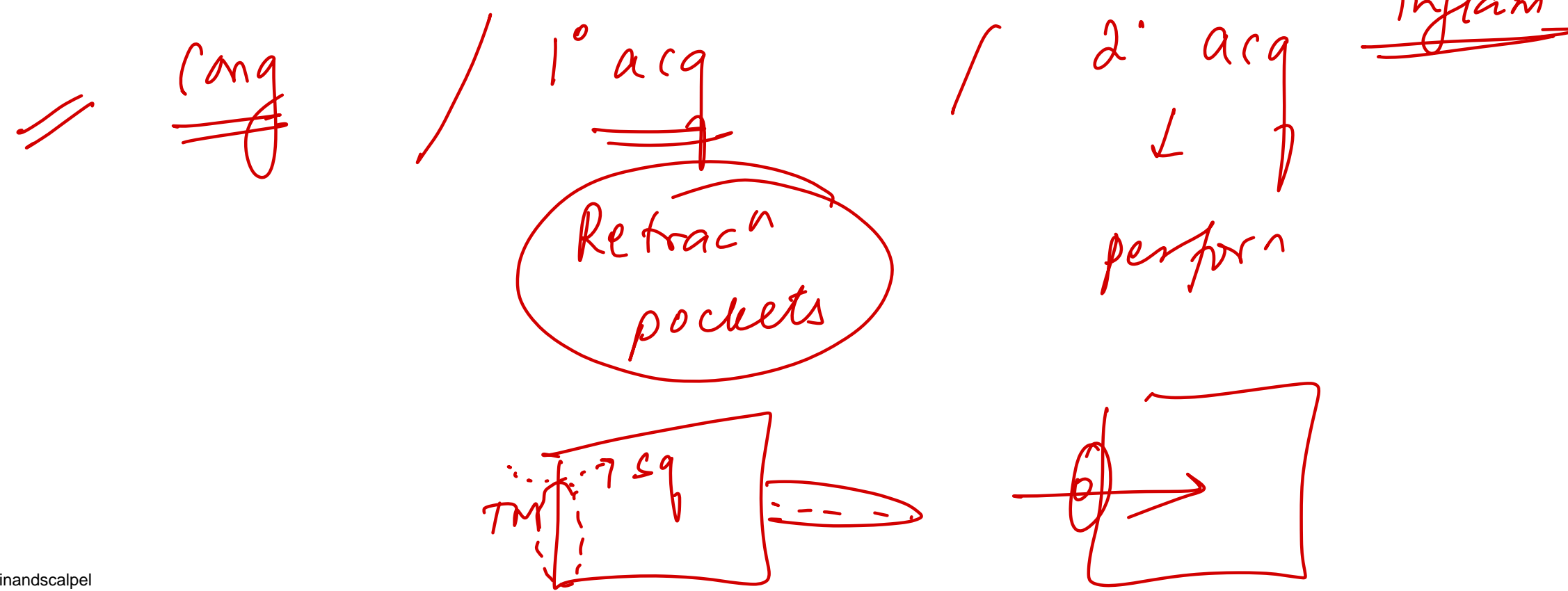
174. All of the following regarding cholesteatoma are correct, except:

~~A.~~ Primary acquired cholesteatoma is due to defect in pars flaccida ~~X~~

B. Congenital cholesteatoma arises from epithelial cell rests

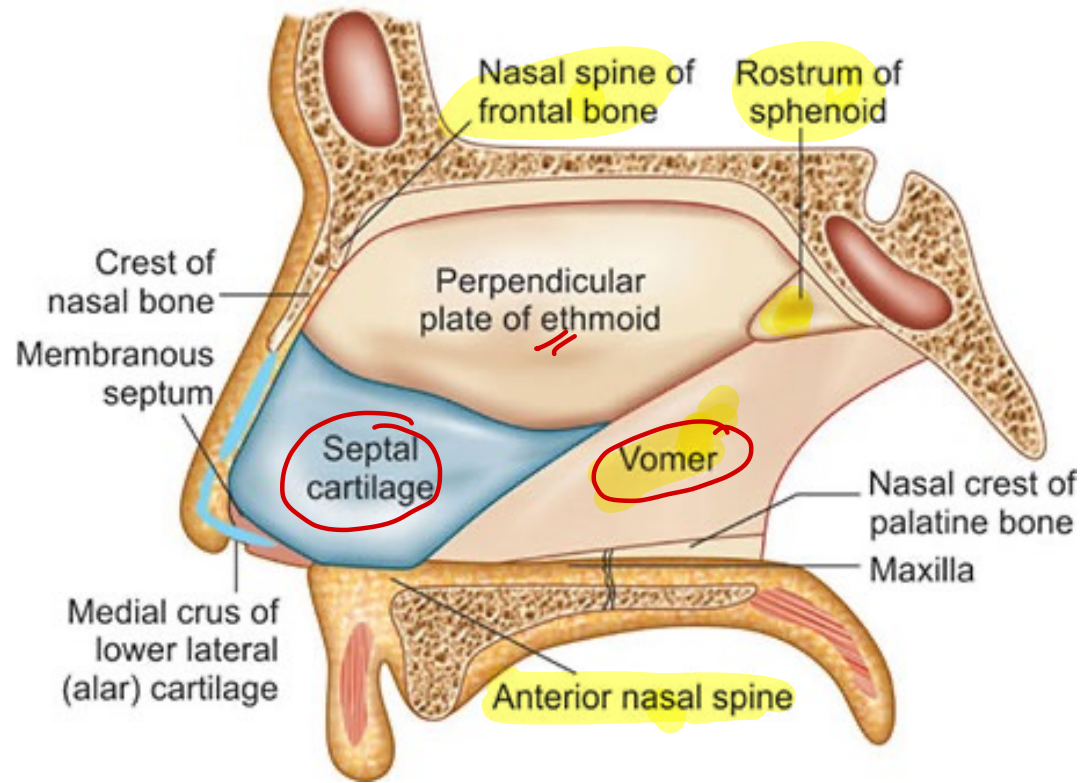
C. Secondary acquired cholesteatoma involves pars tensa

D. Tertiary acquired cholesteatoma originates from retraction pockets → implant<sup>n</sup> of inflam<sup>n</sup>



**176. All of the following contribute to the formation of the nasal septum,  
except:**

- A. Perpendicular plate of ethmoid
- B. Septal cartilage
- ~~C.~~ Inferior nasal concha
- D. Vomer



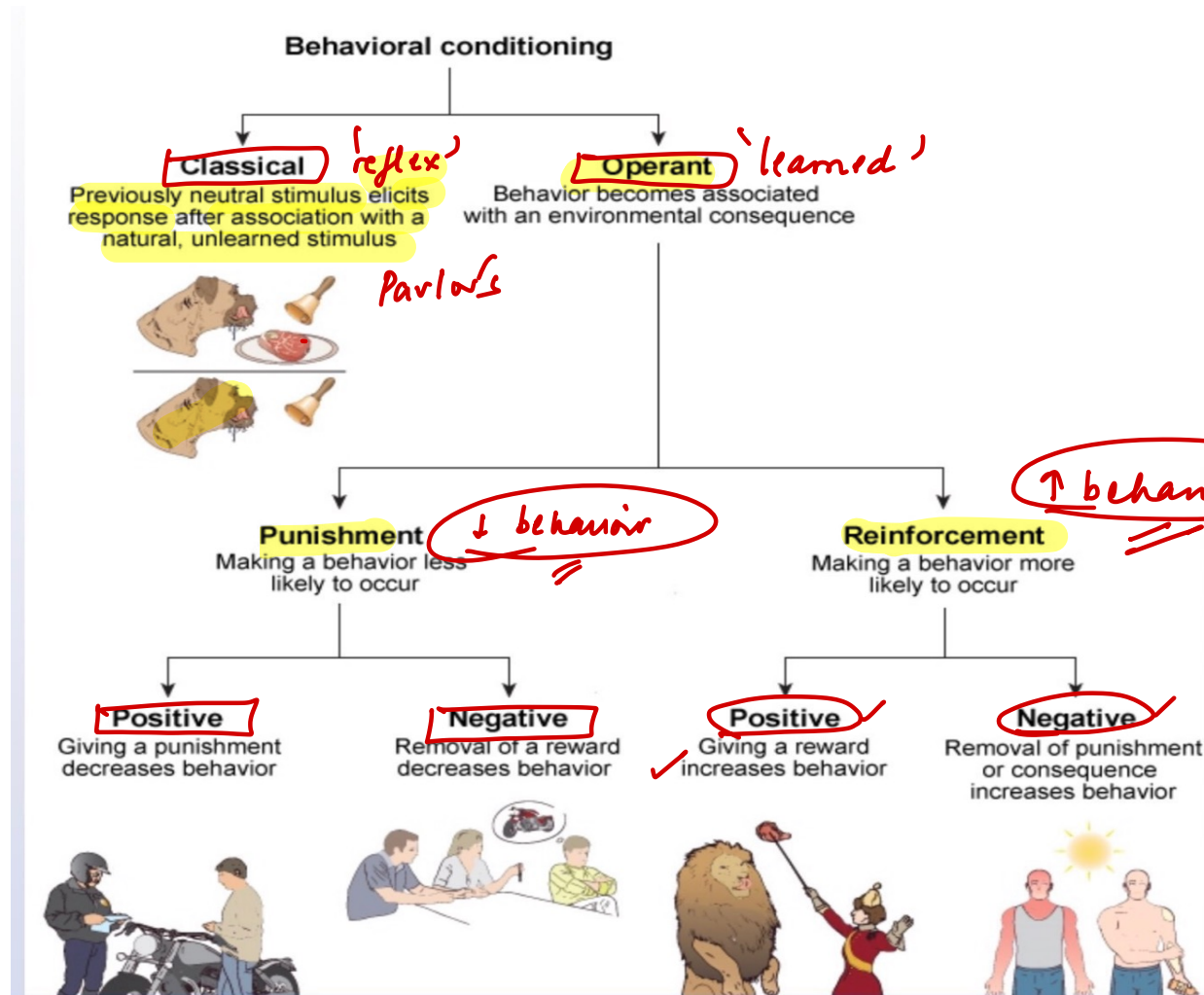
# PSYCHIATRY

---

113. A 25-year-old graduate student with a history of recurrent ear infections as a child feels anxious and sweats when she is in the examination room with her primary care physician. She recently got a roommate, a nursing student, who leaves her stethoscope on the coffee table after returning from class. The patient sweats and feels her heart start to race whenever she sees the stethoscope. This patient's response to her roommate's stethoscope is an example of which of the following phenomena?

- A. Classical conditioning
- B. Negative punishment
- C. Negative reinforcement
- D. Operant conditioning

Type	Add or Remove	Outcome
Positive Reinforcement	Add reward	↑ Behavior
Negative Reinforcement	Remove discomfort	↑ Behavior
Positive Punishment	Add punishment	↓ Behavior
Negative Punishment	Remove reward	↓ Behavior



121. A patient is lying in the hospital without any reaction or response. This behavior can be best described as:

A. Mannerism → goal-oriented mut / caricature

B. Stereotypy = non goal oriented repetitive mut

C. Negativism

D. Echopraxia action

# 120. Subcortical dementia can occur in all of the following conditions except:

A. DLB ✓ SN

B. Huntington's disease ✓ candidate

C. Alzheimer's disease

FTD = Pick's

D. Wilson's disease

✓ MB/BG

**129. A newly married couple has come for counseling as the male partner has had difficulty maintaining an erection until the completion of sexual activity for the past 8 months. Which phase of the normal sexual cycle does this disorder belong to?**

- A. Desire phase
- B. Orgasmic phase
- C. Arousal phase
- D. Resolution phase

Phase	Disorder
<b>1 Desire Phase</b> Libido, sexual interest	<b>Hypoactive Sexual Desire Disorder</b> (also: Sexual Aversion Disorder, Hypersexuality)
<b>2 Arousal Phase</b> Erection (male), Lubrication (female)	<b>Erectile Disorder (ED) Female Sexual Arousal Disorder</b> Causes: vascular, neurological (DM), medications (antihypertensives, SSRIs), psychological
<b>3 Plateau Phase</b> Sustained arousal	
<b>4 Orgasm Phase</b> Ejaculation & climax	<b>Delayed Ejaculation Premature Ejaculation</b> & / <b>Female Orgasmic Disorder</b>
<b>5 Resolution Phase/PAIN PHASE</b>	Genito-pelvic pain disorder/ Penetration disorder

**140. A husband and wife presented to the OPD with complaints of premature ejaculation during intercourse. What is the non-pharmacological technique you will advise to the patient?**

- A. Cognitive behavioral therapy
- B. Exposure and response prevention therapy
- C. Squeeze technique
- D. Sensate focus therapy

# 81. Which of the following features is more in favor of delirium?

A. Occurs gradually over a period of time *Dem*

~~B. Fluctuating course~~


C. Preserved consciousness *Dem*

D. Commonly associated with auditory hallucinations *Dem*  
*verial*

Delirium	Dementia
Hallmark is <u>impaired consciousness</u>	Loss of memory and intellectual abilities
<ul style="list-style-type: none"> <li>• Acute medical illness</li> <li>• Autonomic dysfunction</li> <li>• Abnormal EEG</li> <li>• Carphologia/floccillation (picking at covers/clothes)</li> <li>• Illusion, delusion</li> <li>• Sundowning (worse at night)</li> <li>• Develops quickly</li> <li>• <u>Fluctuating</u> course with lucid intervals</li> </ul>	<p style="text-align: center;">-</p> <p style="text-align: center;"><i>insidious</i></p>

123. A 3-year-old boy is brought to the OPD by his parents due to behavioral difficulties. His mother says, "He is physically healthy and affectionate but has become more defiant and often resists our instructions about getting ready for bed. He plays roughly with his 6-year-old brother and sometimes throws tantrums when he has to share his toys or put them away." His preschool teacher describes him as an "active child" who sometimes talks out loud to classmates while the teacher is speaking. He is easily distracted and often gets up to walk around the classroom. The patient is able to draw circles, speak 3-word sentences, walk up the stairs with alternating feet, and use the toilet, but he cannot wipe himself. His parents express concern about his inability to fully dress himself and about his bed-wetting, which occurs approximately twice a week. Which of the following is the most likely explanation for the child's behavior?

- A. Attention-deficit hyperactivity disorder
- B. Conduct disorder
- C. Disruptive mood dysregulation disorder
- D. Normal development



## Conduct Disorder (CD)

- Persistent violation of societal norms or rights of others


*violent*

## Oppositional Defiant Disorder (ODD)

- Defiant, argumentative, and vindictive behavior **toward authority figures** (parents/teachers)

## Disruptive Mood Dysregulation Disorder (DMDD)

- Severe irritability + frequent temper outbursts
- Between outbursts: mood is **persistently irritable/angry**



## Intermittent Explosive Disorder

- Recurrent episodes of outbursts, out of proportion to provocation, failure to control impulses
- Episodes are not premeditated, provide relief, followed by remorse.
- Between outbursts: mood is **normal**

. A 32-year-old woman comes to the OPD e due to overwhelming anxiety and stress. The patient is an accountant and has been under increasing job-related pressure for the past 6 weeks due to an upcoming tax deadline. She says, "The worst part is that I get really nervous all of a sudden and then feel shaky, dizzy, and nauseated and start to sweat. It happened while I spoke to my boss a few weeks ago, and I had to excuse myself." The patient is especially worried about having an episode during a work meeting, although she notes that her symptoms have also occurred while she was relaxing at home. She says, "I've stopped going out with my friends because I never know when I'm going to feel this way." Blood pressure is 120/70 mm Hg, pulse is 72/min, and respirations are 18/min. Which of the following is the most likely diagnosis?

- A. Acute stress disorder ~~X~~
- B. Adjustment disorder with anxious mood
- C. Generalized anxiety disorder
- D. Panic disorder

< 6 mon

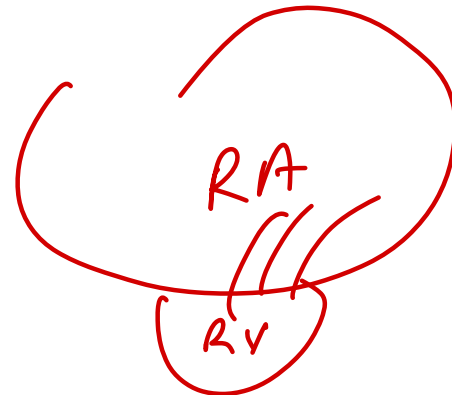
> 6 mon

> 1 mon

54. A 7-year-old boy is evaluated for fatigue. For the last year, he has been avoiding any significant outdoor activities with his peers due to poor energy and shortness of breath. Physical examination shows a holosystolic murmur best heard at the lower sternal border. Echocardiography reveals apical displacement of the tricuspid valve leaflets. Moderate to severe tricuspid regurgitation is also present. If this patient's diagnosis is due to a side effect of a drug taken during pregnancy, his biological mother most likely had which of the following conditions?

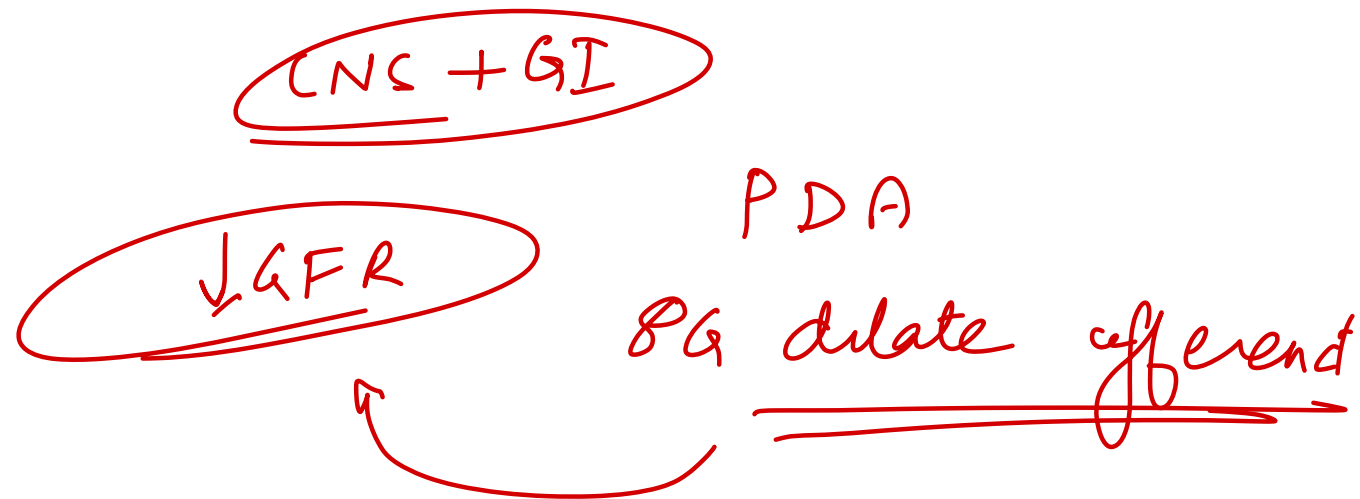
- A. Alcohol abuse
- B. Bipolar disorder
- C. Cocaine abuse
- D. Down syndrome

*Li* → *Ebstein anomaly*



57. A 39-year-old woman is brought to the emergency department after her husband found her confused. The patient was unable to answer questions about why she did not go to work that day and could not remember the day of the week. She has a history of bipolar disorder and has taken the same dose of lithium for the past 10 years. Over the past week, the patient started taking several daily doses of a new medication following a dental extraction. Yesterday, she felt nauseated and vomited twice, and earlier today, she started having diarrhea. Coarse tremors are noted in the upper extremities. Deep tendon reflexes are 2+ in the bilateral extremities. A drug interaction involving which of the following medications is most likely causing this patient's symptoms?

- A. Acetaminophen
- B. ~~Ibuprofen~~ NSAID
- C. Ondansetron
- D. Prednisone



# 98. The FDA approved medication to aid in smoking cessation include all except:

A. NRT-Nicotine Replacement Therapy

B. Bupropion

C. Varenicline

~~D. Buspirone~~

*partial (+) NACh.*

*partial 5HT<sub>1A</sub> (+) anxiolytic*

101. A 37-year-old man is brought to the emergency department by ambulance after his sister found him unresponsive. Several days ago, he was discharged from an inpatient addiction centre, where he was treated for multiple substance use disorders and long-standing bipolar disorder. The patient's sister states that he has been depressed and has not taken any of his prescribed medications since discharge. Temperature is 36.7 C (98.1 F), blood pressure is 80/40 mm Hg, pulse is 62/min, and respirations are 10/min. The patient is obtunded and unresponsive to verbal commands. Physical examination shows 2-mm pupils. The patient is ventilated by bag valve mask, and supplemental oxygen and intravenous fluids are initiated. Which of the following should be administered next?

- A. Buprenorphine
- B. Lithium carbonate
- C. Naloxone
- D. Naltrexone

OPIOD Intox<sup>n</sup>